

BURCU KIM, MBBS  
 NAVEEN SOMIA, MBBS, PhD, FRACS  
*Department of Plastic and  
 Reconstructive Surgery,  
 Prince of Wales Hospital*

JOHN PEREIRA, MBBS, BSc(MED), FRANZCR  
 KUROSH PARSI, MBBS, MSc(MED), PhD,  
 FACP, FACD  
*Department of Medical Imaging  
 Prince of Wales and Sydney Children's Hospital  
 Sydney, Australia*

BURCU KIM, MBBS  
 NAVEEN SOMIA, MBBS, PhD, FRACS  
 JOHN PEREIRA, MBBS, BSc(MED), FRANZCR  
 KUROSH PARSI, MBBS, MSc(MED), PhD,  
 FACP, FACD  
*Faculty of Medicine  
 The University of New South Wales  
 Sydney, Australia*

KUROSH PARSI, MBBS, MSc(MED), PhD,  
 FACP, FACD  
*Department of Dermatology  
 St Vincent's Hospital  
 Sydney Australia*

## Long-term Efficacy and Quality of Life Assessment for Treatment of Axillary Hyperhidrosis With a Microwave Device

In a prior report,<sup>1</sup> we provided 1-year efficacy and safety data for subjects with axillary hyperhidrosis treated with a microwave technology. This letter provides 2-year follow-up data for a majority of those patients and a further exploration of the potential for quality of life improvement.

The original study enrolled 31 adult subjects with primary axillary hyperhidrosis in a single-group unblinded study at 2 centers. All subjects had Hyperhidrosis Disease Severity Scale (HDSS) ratings of 3 or 4 and a gravimetric sweat assessment of at least 50 mg per 5 minutes in each axilla. Baseline Dermatology Life Quality Index (DLQI) scores ranged from 1 to 28, with a mean of 11.8. The subjects were treated with a microwave-based device (miraDry System; Miramar Labs, Sunnyvale, CA). Nineteen of the original study group signed consent for a follow-on Web-based survey for a second year of follow-up that included the HDSS and DLQI questionnaires, and questions on odor reduction. At 1 year after treatment, all side effects (except underarm hair loss) had resolved in all patients who were active in the study. No patients noted any new side effects during the second year.

The results for baseline and each follow-up time point are shown in Table 1. The primary overall efficacy measure was the percentage of subjects who reduced their HDSS scores from 3 or 4 at baseline down to scores of 1 or 2 at the follow-up surveys. This remained greater than 90% and stable.

For the DLQI score, the average score across all patients at baseline was compared with the average score at the indicated follow-up time point, as well as the percentage of patients with at least a 5-point drop in DLQI. In addition, an analysis of the response to individual DLQI questions (percentage of subjects who responded that their activity was “very much” or “a lot” affected by their hyperhidrosis) identified those areas of daily activity that were most impacted by excessive sweat before the treatment: effect on clothing choices (84%), embarrassed or self-conscious (71%), prevented from work or studying (52%), and affected social or leisure activities (45%). After treatment, the percentages were between 0% and 11% and stable, as shown in Table 1.

An analysis for odor reduction was conducted by calculating the percentage of subjects who stated that

TABLE 1. Efficacy Results and Effect on Quality of Life, Measured at Each Visit

Efficacy Measure	Baseline	30 days (n = 30)	3 months (n = 29)	6 months (n = 27)	12 months (n = 26)	15 months (n = 18)	18 months (n = 18)	21 months (n = 18)	24 months (n = 19)
Percent of subjects with HDSS reduction to score of 1 or 2	NA	28/30 = 93.3%	28/29 = 96.6%	26/27 = 96.3%	26/26 = 100%	17/18 = 94.4%	18/18 = 100%	18/18 = 100%	19/19 = 100%
DLQI score (mean ± SD)	11.8 ± 6.4	1.87 ± 2.46	1.86 ± 3.56	1.81 ± 3.43	1.23 ± 1.53	2.00 ± 2.38	1.50 ± 1.72	1.44 ± 1.89	1.37 ± 1.54
Reduction of DLQI score* (mean ± SD)	NA	11.0 ± 4.8	10.7 ± 5.5	10.4 ± 5.94	11.2 ± 5.6	10.3 ± 4.79	11.2 ± 6.6	10.5 ± 5.9	11.4 ± 6.3
Reduction of DLQI by ≥5 points*	NA	25/25 = 100%	23/24 = 96%	21/22 = 95%	21/21 = 100%	13/13 = 100%	13/14 = 93%	13/13 = 100%	14/14 = 100%
DLQI—clothing	84%	10%	3%	7%	0%	0%	0%	0%	11%
DLQI—embarrassed or self-conscious	71%	7%	3%	7%	0%	0%	0%	0%	0%
DLQI—prevented work or studying	52%	0%	3%	0%	0%	0%	0%	0%	0%
DLQI—affected social or leisure	45%	0%	3%	4%	0%	0%	11%	0%	11%
Odor: % with “not a problem”	16%	80%	83%	81%	88%	83%	89%	89%	89%

\*Only included patients who had a baseline DLQI of 5 or greater (excluded 5 patients).

their underarm odor was “not a problem” at the follow-up visits compared with baseline. At baseline, the percentage was 16%; after treatment, this ranged from 80% to 89% (Table 1).

A limitation to this data set is the smaller number of subjects who consented to the follow-on surveys and complied with survey completion—only 61% (19/31) of the treated patients completed the final survey. It is important to note that the majority of the discontinued patients, the 8 patients who declined to consent to the second year of follow-up, had a successful treatment effect at the end of the 1-year follow-up. Their DLQI scores were between 0 and 5; and all had HDSS scores of 1 or 2. Therefore, the cohort that continued into the second year is not biased by unsuccessful patients being excluded.

The effect has been shown to be durable and stable through 2 years of follow-up, and a substantial improvement on quality of life has been documented. This study confirms prior reports<sup>2</sup> regarding specific areas impacted by axillary hyperhidrosis. The tested device represents a new therapeutic option, providing long-term relief for patients suffering from axillary hyperhidrosis.

## References

- Hong HC-H, Lupin M, O’Shaughnessy KF. Clinical evaluation of a microwave device for treating axillary hyperhidrosis. *Dermatol Surg* 2012;38:728–35.
- Solish N, Benohanian A, Kowalski JW. Canadian Dermatology Study Group on Health-Related Quality of Life in Primary Axillary Hyperhidrosis. Prospective open-label study of botulinum toxin type A in patients with axillary hyperhidrosis: effects on functional impairment and quality of life. *Dermatol Surg* 2005;31:405–13.

MARK LUPIN, MD, FRCPC  
*Department of Dermatology and Skin Science  
 University of British Columbia  
 Vancouver, BC, Canada*

H. CHIH-HO HONG, MD, FRCPC  
*Department of Dermatology and Skin Science  
 University of British Columbia  
 Vancouver, BC, Canada*

KATHRYN F. O'SHAUGHNESSY, PhD  
*Miramar Labs, Inc., Sunnyvale, California*

## Fibrohistiocytic Tumors in a Lung Transplant Patient Taking Oral Capecitabine for Nonmelanoma Skin Cancer Chemoprevention

A 67-year-old lung transplant patient with a history of multiple nonmelanoma skin cancers (NMSC) underwent excision of a right scalp squamous cell carcinoma (SCC) with positive deep margins on periosteum. His immunosuppressive regimen included tacrolimus, mycophenolate mofetil, and prednisone. He had taken sirolimus previously, but it was discontinued because of pulmonary toxicity.

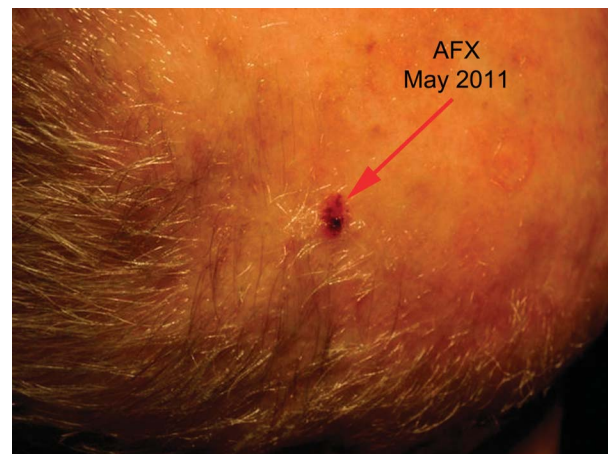
Mohs micrographic surgery (MMS) was performed for his residual SCC, with positive margins on bone, followed by outer table resection and split thickness skin graft (STSG) repair. He completed a course of adjuvant radiation, complicated by radiation dermatitis, graft rejection requiring increased immunosuppression, and herpes zoster.

After these complications resolved, the patient began taking acitretin 10 mg daily for NMSC chemoprevention. However, he rapidly developed 5 new SCCs and a basal cell carcinoma (BCC), which were treated with MMS. After his acitretin dose was increased to 20 mg daily, he did not develop new NMSCs. However, he could not tolerate the higher dosage, and maintenance therapy at 10 mg daily was ineffective. Acitretin was discontinued and he was started on capecitabine 1 g twice daily. Over the next 15 months, he developed 2 SCCs, 2 BCCs, 2 atypical fibroxanthomas (AFXs) of the left scalp vertex and right cheek (Figures 1 and 2), and a malignant fibrous histiocytoma (MFH) of the right scalp vertex (Figure 3), which were treated with MMS. The MFH arose adjacent to the scalp SCC previously treated

with surgery and radiation (Figure 3). It had positive margins on bone, requiring inner table resection, wider excision, titanium mesh placement, and free flap repair. He subsequently developed SCCs of his nose and left cheek, which were also treated with MMS. His capecitabine was discontinued, and he was restarted on acitretin 10 mg daily. There was no evidence of MFH recurrence at that time. The patient developed increasing shortness of breath and died of graft-versus-host-disease 15 months after his MFH resection.

### Discussion

Capecitabine is an oral 5-fluorouracil (5-FU) prodrug that is converted to its active metabolite, 5-FU, by thymidine phosphorylase and works by irreversibly inhibiting thymidylate synthase. A significantly



**Figure 1.** AFX left scalp vertex. Crusted erythematous  $0.8 \times 0.8$ -cm papule at least 5 to 8 cm away from the original moderately differentiated SCC and subsequent lesions.