

## Original article

# Prepectoral direct-to-implant breast reconstruction with complete ADM or synthetic mesh coverage – 36-Months follow-up in 200 reconstructed breasts



Roland Reitsamer<sup>a,\*</sup>, Florentia Peintinger<sup>b</sup>, Frederike Klaassen-Federspiel<sup>a</sup>, Andreas Sir<sup>a</sup>

<sup>a</sup> Breast Center Salzburg, University Hospital Salzburg, Paracelsus Medical University Salzburg, Salzburg, Austria

<sup>b</sup> Department of Gynecology and Obstetrics, General Hospital Leoben, Leoben, Austria

## ARTICLE INFO

## Article history:

Received 11 May 2019

Received in revised form

21 July 2019

Accepted 19 August 2019

Available online 20 August 2019

## ABSTRACT

**Background:** Prepectoral implant placement is an innovative option for breast reconstruction, due to multiple advantages over subpectoral implant placement. The adoption of various ADMs and meshes supports the utilization of the prepectoral technique.

**Methods:** 200 breasts were reconstructed with prepectoral implant placement after nipple-sparing mastectomy in a one-stage direct-to-implant procedure. The implants were completely covered and fixed with porcine ADMs (Strattice™ or Artia™), or with synthetic meshes (TIGR®). The pectoralis major muscle was not detached at all and kept intact entirely.

**Results:** Minor complications included minimal nipple necrosis without further intervention and complete healing in 14 breasts (7.0%). Major complications comprised implant loss due to skin necrosis and wound infection in 7 breasts (3.5%), and hematoma with revision surgery in 8 breasts (4.0%). At a mean follow-up of 36 months cosmetic results were excellent and good in 180 breasts (90.0%), sufficient in 13 breasts (6.5%) and insufficient in 7 breasts (3.5%). Breast animation deformity and implant displacement could not be observed, while implant rotation was documented in 5 breasts (2.5%). Capsular contractures grade III or IV could not be observed neither in patients with previous radiotherapy nor in patients with radiotherapy to the reconstructed breast.

**Conclusions:** The single-stage direct-to-implant prepectoral implant placement after NSM with complete coverage of the implant with ADM or synthetic mesh represents a novel and feasible technique for breast reconstruction. This technique provides an alternative to the subpectoral implant placement with excellent cosmetic results avoiding the disadvantages of the subpectoral implant placement.

© 2019 Elsevier Ltd. All rights reserved.

## 1. Introduction

Nipple-sparing mastectomy (NSM) evolved to the standard technique for patients, whose breast glands have to be removed for several reasons, as the skin envelope is not the organ at risk and therefore can be preserved. A conventional mastectomy has to be performed in rare remaining cases. The oncologic safety of NSM was demonstrated in multiple reports [1]. An integral part of the NSM technique is the immediate breast reconstruction. Implant-based breast reconstruction is the method of choice in more than 80% of patients after conservative mastectomy. The subpectoral

implant placement was standard of care for many decades. The subpectoral implant placement with complete muscle coverage using the pectoralis major muscle (PMM), parts of the serratus muscle and the fascia of the rectus muscle, performed with multiple variations, results in a moderate cosmetic outcome, is painful for the patient and the surgical procedure is more complex. The partial implant coverage with the PMM for the upper pole and partial coverage with acellular dermal matrix (ADM) for the lower pole results in much better cosmesis, especially in patients with a mild to moderate ptosis or no ptosis at all. The consideration of the insertion of an ADM is to cover the lower pole of the implant, to stabilize the dissected PMM and to serve as a hammock for the implant. As a consequence of the variance of the origin of the PMM, the percentage of coverage with the PMM can vary significantly from two thirds of the implant to only on third of the implant [2,3]. Other disadvantages of the subpectoral implant placement remain,

\* Corresponding author. Breast Center Salzburg, University Hospital Salzburg, Paracelsus Medical University Salzburg, Muellner Hauptstrasse 48, 5020, Salzburg, Austria.

E-mail address: [r.reitsamer@salk.at](mailto:r.reitsamer@salk.at) (R. Reitsamer).

as there are the dissection and elevation of the PMM, the reduction of muscle strength, postoperative pain, longer recovery period, and the breast animation deformity during contraction of the PMM. The prepectoral implant placement emerged for those reasons, and the subpectoral implant placement is questioned as muscle-sparing techniques evolved in many other fields of plastic surgery. The prepectoral implant placement without any detachment of the PMM requires an implant coverage and an implant fixation with tissue support. This can be performed with ADMs, meshes or autologous dermofat flaps. In the past few years, operation techniques changed, the implant quality improved, ADMs and various meshes became available and together facilitated superior aesthetic outcomes with the prepectoral implant placement. Single-stage direct-to-implant (DTI) prepectoral breast reconstruction is a perfect option for patients who want to maintain their breast sizes, and do not want their breasts to be augmented, but is also possible for patients with large and ptotic breast who desire breast reduction. Most publications on prepectoral implant placement report on two-stage expander to implant breast reconstruction [4–6]. We exclusively report on single-stage DTI breast reconstruction after NSM.

## 2. Patients and methods

From April 2013 to November 2018 we performed a series of 200 consecutive NSMs and direct-to-implant breast reconstructions with prepectoral implant placement and complete implant coverage either with the porcine ADMs, Strattice™ or Artia™, or with the synthetic surgical mesh, TIGR® Matrix. After informed consent all patients decided against PMM detachment or dissection, and agreed to prepectoral implant placement. In 134 patients and 200 breasts NSM and single-stage DTI breast reconstruction with prepectoral implant placement was performed. The mean age of the patients was 45.1 years (min 25, max 74 years). Sixty-six of 134 (49.3%) patients were treated with bilateral mastectomy, and 68/134 (50.7%) patients were treated with unilateral mastectomy. Fifty-one of 134 (38.0%) patients were BRCA 1 and/or BRCA2 mutation carriers. Twenty-four of those patients were diagnosed with unilateral breast cancer and received bilateral NSM. Nineteen of the mutation carriers received bilateral risk-reducing mastectomy. Sixteen patients without mutation (19.3%) and a unilateral invasive breast cancer chose an additional contralateral risk-reducing mastectomy because of excessive concern of a second breast cancer in the contralateral breast or due to a remarkable family history of breast cancer without BRCA gene mutation. In 62/200 (31.0%) of the operated breasts, the patients received preoperative chemotherapy. Fifty-eight of 200 (29.0%) breasts received some form of radiotherapy, 32/200 (16.0%) breasts had radiotherapy after NSM and DTI reconstruction. Twenty-six of 200 (13.0%) breasts had a history of radiotherapy and recurrent invasive breast cancer or recurrent DCIS and were treated with NSM and DTI. The mean volume of the removed breasts was 342 ml (range 59–1092 ml) and the mean implant weight was 340 g (range 110–735 g). Nipple-sparing mastectomy was performed in all patients. In the majority of operations (79.5%) inframammary fold incision was chosen, which is the standard incision for most of our patients. In some cases lateral s-shaped incisions (7.0%), vertical incisions (3.5%) or batwing incisions (2.5%) were performed, depending on former incision for lumpectomy or segmentectomy, or when partial skin excision was necessary (Table 1). In few cases (7.5%) Wise incision for reduction mastopexy was performed. In those cases the prepectoral implant was covered partly with autologous dermofat flap and partly with ADM or synthetic mesh.

**Table 1**

Age, Breast volume, Implant weight, Incision type, Radiotherapy.


Age mean, years	45
Age min, years	25
Age max, years	74
NSM bilateral, n patients	66
NSM unilateral, n patients	68
Breast volume excised mean, ml	342
Breast volume excised min, ml	59
Breast volume excised max, ml	1092
Implant weight mean, g	340
Implant weight min, g	110
Implant weight max, g	735
Incision type	
Inframammary fold incision, n breasts, (%)	159 (79.5%)
Lateral s-shaped incision, n breasts, (%)	14 (7.0%)
Vertical incision, n breasts, (%)	7 (3.5%)
Wise incision, n breasts, (%)	15 (7.5%)
Batwing incision, n breasts, (%)	5 (2.5%)
Radiotherapy (RTX)	
RTX after NSM + Reconstruction, n breasts, (%)	32 (16.0%)
NSM + Reconstruction after prior RTX, n breasts, (%)	26 (13.0%)

## 3. Prospective data-base

Data were retrieved from a prospectively maintained data-base. Exclusively patients with NSM and single-stage direct-to-implant breast reconstruction are included in this report. We excluded patients with two stage expander/implant reconstruction and we excluded patients with skin sparing mastectomy, or areola-sparing mastectomy.

## 4. Technique

The NSM was performed with electrocautery device to dissect the breast gland from the PMM in the first step and with blunt scissors to dissect the gland from the skin flap in the plane of the Scarpa fascia in the second step. With this technique thermal injury of the skin can be avoided, the best blood supply of the skin flaps can be achieved and skin perfusion can be protected. Then the complete breast gland was dissected peripherally with sufficient exposure of the axillary tail. After ablation, the volume and the weight of the breast gland were measured, and the final implant size was determined according to these measurements. As most patients wanted their reconstructed breasts looking natural and alike their original breasts, anatomical implants and implant sizes resembling the removed breast volumes were used. The PMM was left entirely intact and the pocket was washed with saline only. The ADM or the synthetic mesh was prepared for the coverage of the implants. We used either the porcine ADMs Strattice™ or Artia™ reconstructive tissue matrices (LifeCell™ Corporation, Bridgewater, NJ, USA). Since ADMs in the desired size were not available in Europe, two sheets of Strattice™ 8 × 16 cm or Artia™ 8 × 16 cm were joined by suturing the long sides of the two sheets with interrupted Vicryl® 3/0 sutures after thorough washing of the ADMs in saline thoroughly. The enlarged 16 × 16 cm ADM was incised twice on each longitudinal edge and trimmed as illustrated in Fig. 1a. This type of incision allowed to create four straight flaps (to be fixed by sutures) and four angular flaps at the corners (to be wrapped around the implant). This enlarged sheet of ADM was then placed and fixed to create the anterior implant pocket. The superior straight flap of the ADM was fixed to the tight connective tissue between the fascia of the PMM and the superficial thoracic fascia with three interrupted sutures after marking the optimal suture sites from outside. The ADM was meshed with a scalpel to make it more pliable, to fit closer over the implant and to facilitate the fluid transfer from the pocket to the superficial layer where the



**Fig. 1.** a: Implant wrapping with ADM. b: Implant wrapping with synthetic mesh.

drain was placed. In the next step the medial straight flap of the ADM was sutured to the fascia with three sutures. Then the implant with the appropriate size was placed prepectorally beneath this ADM envelope. We used highly cohesive anatomically shaped silicone gel-filled implants (Allergan®, Inc., Irvine, California, USA, or Polytech® implants, Dieburg, Germany). The angular ADM flaps were wrapped around the implant medial-cranially and medial-caudally as well as lateral-cranially and lateral-caudally, in a way that a complete ADM-covered implant pocket could be achieved. Then three sutures fixed the lateral straight flap, and in the final step three interrupted sutures were used to fix the caudal straight flap to the fascia to define the inframammary fold. Careful attention is essential to keep the ADM tightly fitting around the implant and to avoid wrinkle formation of the ADM. With this suture technique the implant can be kept in an exact position and an implant malposition can be prevented. One suction drain was inserted and a double layer wound closure was performed with Monocryl® 4.0 interrupted sutures and Monocryl® 5.0 running sutures for skin closure. After wound dressing all patients were adequately supplied with a surgical compression bra or a soft dressing bandage. The drain was removed when less than 20 ml of wound fluid was produced within 24 h.

If the synthetic matrix TIGR™ (Novus Scientific AB, Uppsala, Sweden, 10 × 15cm or 20 × 30cm) was used, the mesh was trimmed and incised in a similar way, but the mesh was fixed with 3 sutures at the superior edge of the mesh only. Then the implant was put in place and the excessive mesh was wrapped around the

implant completely, and no further sutures were performed (Fig. 1b). TIGR™ matrix is a long-term resorbable, synthetic surgical mesh with dual-stage degradation and full resorption, containing of fast resorbing fibers and slow resorbing fibers. The fast resorbing fibers lose mechanical strength in a couple of weeks and completely resorb within 4 months, the slow resorbing fibers stay strong at least 6 months and completely resorb in 3 years. ADM was used in 113 (56.5%) breasts and TIGR™ matrix was used in 87 (43.5%) breasts. The use of ADM or synthetic mesh was left up to the discretion of the surgeon.

## 5. Results

In total 200 breasts were reconstructed by using the described procedure. Postoperative complications (Table 2) included minor complications with minimal nipple necrosis without further intervention followed by complete healing in 14 breasts (7.0%), and major complications including implant loss in 7 breasts (3.5%) and hematoma with revision surgery and evacuation in 8 breasts (4.0%). Breast pain was not recorded and analgesics were not required after surgery, except for the patients with hematoma. Arm-shoulder mobility showed no restrictions and no motion-associated pain was reported. Mean duration of drainage was five days (range 3–12 days). Seroma formation could be observed in 29/200 breasts (14.5%). The seroma had to be punctured once in 15 breasts (7.5%), twice in 7 breasts (3.5%) and more often than twice in 7 breasts (3.5%), respectively.



**Table 2**  
Complications.

	Prior Radiotherapy n = 26	%	No prior Radiotherapy n = 174	%	Total n = 200	%
<b>Minor complications</b>						
Minimal nipple necrosis	2	7.7	12	6.9	14	7.0
<b>Major complications</b>						
Hematoma	3	11.5	5	2.9	8	4.0
Implant loss	1	3.8	6	3.4	7	3.5
<b>Total</b>	6	23.1	23	13.2	29	14.5

After a mean follow-up of 36 months (range 3–68 months) cosmetic results were excellent for 117 breasts (58.5%), good for 63 breasts (31.5%), sufficient for 13 breasts (6.5%) and insufficient for 7 breasts (3.5%) on a four score scale for cosmetic evaluation (Fig. 2). The scale for aesthetic outcome was patient and physician related and photographs were taken (1 excellent, 2 good, 3 sufficient, 4 insufficient). In most of the cases the rating matched between patient and physician. If the rating did not match the worse rating was used. Breast animation could not be observed when the patients contracted their PMMs. Implant displacement occurred in none of the patients, while implant rotation could be observed in 5 patients (2.5%). The implant rims were visible and palpable in the upper poles of the breasts in 3 very skinny patients, and rippling could be observed in 2 other very skinny patients, but even those patients were pleased with the cosmetic result. Lipofilling for cosmetic reasons was performed in 7 patients (3.5%).

Thirty-two (16.0%) patients received postoperative radiotherapy to one breast (Fig. 3). Thirty-one patients did not have severe radiotherapy-induced side effects. In one patient the implant had to be removed 4 weeks after radiotherapy due to massive swelling, edema and infection. Capsular contractures grade III or IV could not be observed, and cosmetic results were excellent at the short term follow-up. Twenty-six (13.0%) patients had prior radiotherapy to one breast. Six (23.0%) of those 26 breasts developed some kind of complication, 4/26 (15.3%) developed major complications. One patient suffered implant loss, three patients developed hematoma with revision surgery, and 2/26 (7.7%) showed minimal nipple necrosis. Otherwise 23/174 (13.2%) breasts without prior radiotherapy developed some kind of complication, and 11/174 (6.3%) developed major complications (Table 2). There were no differences in complication rates nor in cosmetic results according to the utilization of ADMs or synthetic meshes.

## 6. Discussion

In the last decade a shift from the conventional mastectomy technique to the skin preserving techniques as NSM or SSM occurred. The implant-based breast reconstruction is an essential part of the skin preserving mastectomy techniques. Yet in the seventies the question of subcutaneous or subpectoral prosthesis positioning and single-stage breast reconstruction was discussed [7,8]. The subpectoral implant placement was the preferred placement to cover the implant with multiple muscles of the thoracic wall. However, the subpectoral implant placement is an unnatural position of the implant, and the female breast is overlying the PMM eventually. For cosmetic and device dependent reasons, the subpectoral implant placement was standard of care for many years. The superiority of subpectoral implant placement is being questioned due to improvements in implant technology, ADMs, and surgical techniques. Pain and discomfort after detachment of the PMM are well known postoperative complaints. Animation deformities while PMM contraction are a common side effects. The substantial strength loss of the PMM and the muscular deficit in women with subpectoral prosthetic breast reconstruction are adequately described [9]. There is no data supporting subpectoral implant placement to be superior to prepectoral implant placement for breast reconstruction. For prepectoral implant placement, the ADM serves as soft tissue support, by acting as a tissue regeneration interlayer between the skin and the implant. The ADM prevents breast implant displacement and minimizes the implant edge prominence. The development of form-stable silicone gel-filled breast implants and the advent of various acellular dermal matrices enable the prepectoral implant placement with complete wrapping of the implant and therefore the reconstruction of a natural looking soft breast without detaching the PMM. Capsular fibrosis is a well-known problem of implant based breast reconstruction, and there are some reports that the additional use of

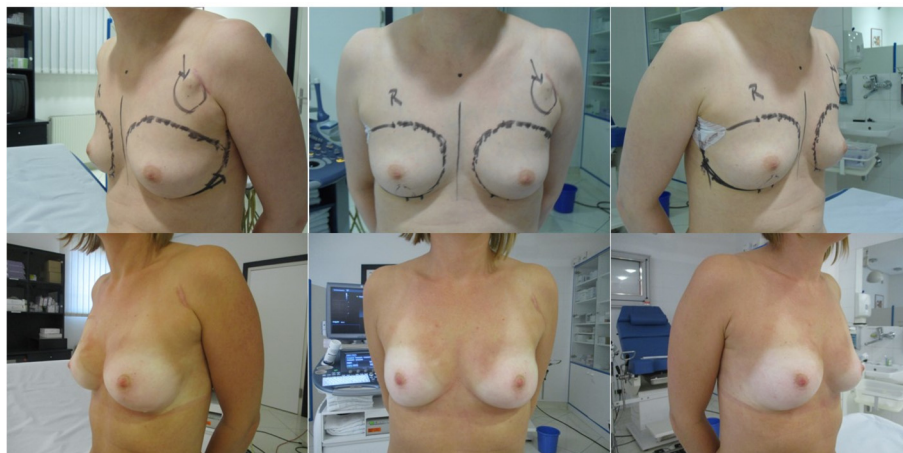

Fig. 2. Cosmetic result, bilateral NSM no radiotherapy.

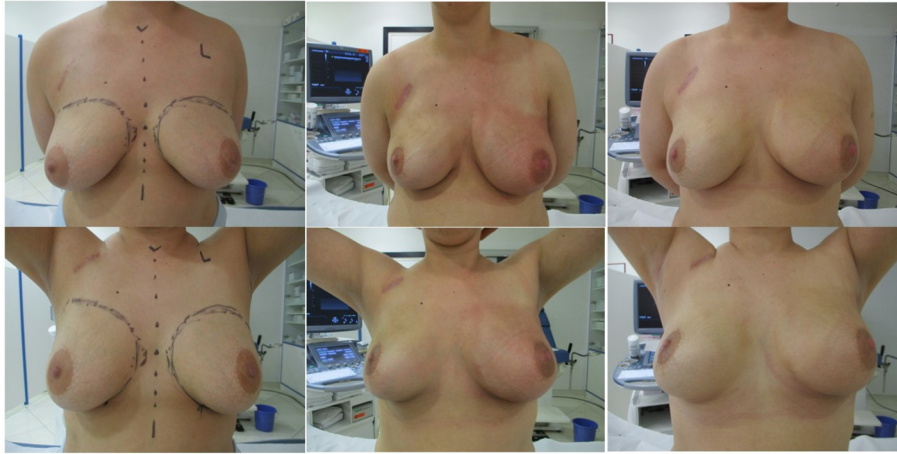


Fig. 3. Cosmetic result, bilateral NSM and postoperative radiotherapy to the left breast.

ADM could further reduce the capsular contracture rate [10–14]. Furthermore there are reports on reduced capsule formation in patients with ADM envelope and postoperative radiotherapy [15,16]. ADM may slow the progression of capsule formation, fibrosis and contraction via a decreased radiation-related inflammation [12,13]. The total wrapping of the breast implants with ADM as a preventive tool against capsular contracture was experimentally performed in rats, with promising results. The prevention of capsular contracture formation with the application of ADMs predestines the prepectoral approach and complete ADM coverage. In our experience no capsular contracture Baker grade III or IV could be observed in patients who received radiotherapy. Recent publications on prepectoral implant placement and postmastectomy radiotherapy show promising results [6,16]. Most publications on prepectoral placement are reports on two-stage breast reconstruction [4–6,16]. There are only few reports on prepectoral implant placement in a one-stage procedure [17–28], with different approaches to cover the implant. Coverage techniques with various ADMs or with titanized polypropylene meshes or with synthetic absorbable meshes are described. The study from Casella et al. [20] using TiLoop® Bra either in a standard subpectoral or in a prepectoral approach and complete coverage could not find differences according surgical complication rates in the short-term follow-up. Further follow-up, cosmetic results, patient reporting outcome, complication rates and local recurrence rates were reported recently and show promising results for the prepectoral implant placement [21]. Other groups used a prefabricated ADM pocket Braxon® for a prepectoral placement of the completely wrapped implant [23–25] with excellent results. The use of human ADM [17,26,28] or porcine ADM [18,27] for the complete coverage and prepectoral placement was described in smaller studies and complication rates were comparable for subpectoral and prepectoral implant placement, but negative side effects of the subpectoral implant placement could be prevented by the prepectoral implant placement. Highton et al. [27] using a similar technique as we describe, reported on 103 prepectoral DTI breast reconstructions with porcine ADM coverage, and minor complications in 8.4% and major complications with implant loss in 4.4% after a mean follow-up of 485 days. These results are nearly identical to our results in 200 prepectoral DTI breast reconstructions and minor complications in 7.0%, and major complications in 7.5% (3.5% implant loss and 4.0% revision surgery) after 36 months median follow-up. Jones et al. [28] recently reported on 73 prepectoral DTI procedures with human ADM, and major complications with implant loss in 2.7%. For TIGR® matrix there is only one

report in a small series of 65 breast reconstructions in one-stage or two-stage procedure, with minor complications in 17% and major complications in 6.2% [29]. These complication rates are comparable to reported complication rates on ADMs or synthetic non-absorbable meshes.

Many surgeons advocate the two-stage breast reconstruction. The advantage and disadvantage are discussed repeatedly. We favor the direct-to-implant single-stage breast reconstruction as most women a second procedure can be spared. In our experience most women preferred an identical breast size after NSM. In those women or women with a desire for slight augmentation DTI reconstruction easily can be performed in a one-stage procedure. However in women with desire for breast reduction after NSM, the DTI procedure can be performed either. In those patients a conventional reduction pattern with an autologous dermofat-flap for the lower pole coverage and an ADM or mesh coverage for the upper pole can be performed as described by other authors likewise [30,31]. In this large series we report on DTI prepectoral implant placement after NSM. Our results on complication rates are reasonable and comparable to subpectoral implant placement. The cosmetic results are appealing, the most displeasing side effect is the rippling, especially in a bent forward position. This rippling can be improved by fat grafting easily. However rippling is not only observed in prepectoral implant placement, but also in subpectoral implant placement, as the PMM atrophies over time.

## 7. Conclusion

Prepectoral direct-to-implant breast reconstruction after NSM is a promising and feasible method which allows the reconstruction of a soft, appealing and good-looking breast in most women. Advantages are intact thoracic musculature, less postoperative pain, no breast animation deformity, and in most cases one single surgical procedure. Complication rates are low and reasonable. Ideal candidates for this technique are patients with small to moderate non ptotic breasts and good soft tissue skin envelope. Short-term and mid-term follow-up is very promising, long-term follow-up has to be reported.

## References

- [1] Headon HL, Kasem A, Mokbel K. The oncologic safety of nipple-sparing mastectomy: a systematic review of the literature with a pooled analysis of 12,358 procedures. *Arch Plast Surg* 2016 Jul;43(4):328–38.
- [2] Madsen Jr RJ, Chim J, Ang B, Fisher O, Hansen J. Variance in the origin of the pectoralis major muscle: implications for implant-based breast

- reconstruction. *Ann Plast Surg* 2015;74(1):111–3.
- [3] Baek Wy, Byun IH, Seok Kim Y, Jung BK, Yun IS, Roh TS. Variance of the pectoralis major in relation to the inframammary fold and the pectoralis minor and its application to breast surgery. *Clin Anat* 2017 Apr;30(3):357–61.
  - [4] Sbitany H, Piper M, Lentz R. Prepectoral breast reconstruction: a safe alternative to submuscular prosthetic reconstruction following nipple-sparing mastectomy. *Plast Reconstr Surg* 2017 Sep;140(3):432–43.
  - [5] Salibian AH, Harness JK, Mowlds DS. Staged suprapectoral expander/implant reconstruction without acellular dermal matrix following nipple-sparing mastectomy. *Plast Reconstr Surg* 2017 Jan;139(1):30–9.
  - [6] Sigalove S, Maxwell GP, Sigalove NM, et al. Prepectoral implant-based breast reconstruction: rationale, indications, and preliminary results. *Plast Reconstr Surg* 2017 Feb;139(2):287–94.
  - [7] Hüter J, Clemens H, Ogbukagu A. Subcutaneous or subpectoral prosthesis positioning? *Arch Gynecol* 1979;228(1–4):290.
  - [8] Apfelberg DM, Laub DR, Maser MR, Lash H. Submuscular breast reconstruction – indications and techniques. *Ann Plast Surg* 1981;7(3):213–21.
  - [9] De Haan A, Toor A, Hage JJ, Veeger HE, Woerdeman LA. Function of the pectoralis major muscle after combined skin-sparing mastectomy and immediate reconstruction by subpectoral implantation of a prosthesis. *Ann Plast Surg* 2007;59(6):605–10.
  - [10] Stump A, Holton III LH, Connor J, Harper JR, Slezak S, Silverman RP. The use of acellular dermal matrix to prevent capsule formation around implants in a primate model. *Plast Reconstr Surg* 2009;124:82–91.
  - [11] Komorowska-Timek E, Oberg KC, Timek TA, Gridley DS, Miles DA. The effect of AlloDerm envelopes on periprosthetic capsule formation with and without radiation. *Plast Reconstr Surg* 2009;123:807–16.
  - [12] Schmitz M, Bertram M, Kneser U, Keller AK, Horch RE. Experimental total wrapping of breast implants with acellular dermal matrix: a preventive tool against capsular contracture in breast surgery? *J Plast Reconstr Aesthet Surg* 2013;66(10):1382–9.
  - [13] Cheng A, Lakhiani C, Saint-Cyr M. Treatment of capsular contracture using complete implant coverage by acellular dermal matrix: a novel technique. *Plast Reconstr Surg* 2013;132(3):519–29.
  - [14] Salzberg CA, Ashikari AY, Berry C, Hunsicker LM. Acellular dermal matrix-assisted direct-to-implant breast reconstruction and capsular contracture: a 13-year experience. *Plast Reconstr Surg* 2016 Aug;138(2):329–37.
  - [15] Tang R, Coopey SB, Colwell AS, et al. Nipple-sparing mastectomy in irradiated breasts: selecting patients to minimize complications. *Ann Surg Oncol* 2015;22(10):3331–7. Oct.
  - [16] Elswick SM, Harless CA, Bishop SN, et al. Prepectoral implant-based breast reconstruction with postmastectomy radiation therapy. *Plast Reconstr Surg* 2018 Jul;142(1):1–12. <https://doi.org/10.1097/PRS.0000000000004453>.
  - [17] Colwell AS, Damjanovic B, Zahedi B, Medford-Davis L, Hertl C, Austen Jr WG. Retrospective Review of 331 consecutive immediate single-stage implant reconstructions with acellular dermal matrix: indications, complications, trends, and costs. *Plast Reconstr Surg* 2011 Dec;128(6):1170–8.
  - [18] Reitsamer R, Peintinger F. Prepectoral implant placement and complete coverage with porcine acellular dermal matrix: a new technique for direct-to-implant breast reconstruction after nipple-sparing mastectomy. *J Plast Reconstr Aesthet Surg* 2015 Feb;68(2):162–7.
  - [19] Berna G, Cawthorn SJ, Papaccio G, Balestrieri N. Evaluation of a novel breast reconstruction technique using the Braxon® acellular dermal matrix: a new muscle-sparing breast reconstruction. *ANZ J Surg* 2017 Jun;87(6):493–8.
  - [20] Casella D, Bernini M, Bencini L, et al. TiLoop®Bra mesh used for immediate breast reconstruction: comparison of retropectoral and subcutaneous implant placement in a prospective single-institution series. *Eur J Plast Surg* 2014;37(11):599–604.
  - [21] Casella D, Di Taranto G, Marcasciano M, et al. Evaluation of prepectoral implant placement and complete coverage with TiLoop®Bra mesh for breast reconstruction: a prospective study on long-term and patient reported BREAST-Q outcomes. *Plast Reconstr Surg* 2019 Jan;143(1):1e–9e. <https://doi.org/10.1097/PRS.0000000000005078>.
  - [22] Casella D, Di Taranto G, Marcasciano M, et al. Nipple-sparing bilateral prophylactic mastectomy and immediate reconstruction with TiLoop®Bra mesh in BRCA1/2 mutation carriers: a prospective study of long-term and patient reported outcomes using the BREAST-Q. *Breast* 2018 Jun;39:8–13.
  - [23] Vidya R, Masià J, Cawthorn S, et al. Evaluation of the effectiveness of the prepectoral breast reconstruction with Braxon dermal matrix: first multi-center European report on 100 cases. *Breast J* 2017 Nov;23(6):670–6.
  - [24] Onesti MG, Maruccia M, Di Taranto G, et al. Clinical, histological, and ultrasound follow-up of breast reconstruction with one-stage muscle-sparing “wrap” technique: a single-center experience. *J Plast Reconstr Aesthet Surg* 2017 Nov;70(11):1527–36.
  - [25] Bernini M, Calabrese C, Cecconi L, et al. Subcutaneous direct-to-implant breast reconstruction: surgical, functional, and aesthetic results after long-term follow-up. *Plast Reconstr Surg Glob Open* 2016 Jan 7;3(12):e574. <https://doi.org/10.1097/GOX.0000000000000533>.
  - [26] Downs RK, Hedges K. An alternative technique for immediate direct-to-implant breast reconstruction – a case series. *Plast Reconstr Surg Glob Open* 2016;4(7):e821. <https://doi.org/10.1097/GOX.0000000000000839>. Jul 22.
  - [27] Highton L, Johnson R, Kirwan C, Murphy J. Prepectoral implant-based breast reconstruction. *Plast Reconstr Surg Glob Open* 2017 Sep 19;5(9):e 1488. <https://doi.org/10.1097/GOX.0000000000001488>.
  - [28] Jones G, Yoo A, King V, et al. Prepectoral immediate direct-to-implant breast reconstruction with anterior AlloDerm coverage. *Plast Reconstr Surg* 2017 Dec;140:31S–8S. <https://doi.org/10.1097/PRS.0000000000004048> (6S Prepectoral Breast Reconstruction).
  - [29] Hallberg H, Lewin R, Elander A, Hansson E. TIGR® matrix surgical mesh – a two-year follow-up study and complication analysis in 65 immediate breast reconstructions. *J Plast Surg Hand Surg* 2018 Aug;52(4):253–8.
  - [30] Nava MB, Ottolenghi J, Pennati A, et al. Skin/nipple sparing mastectomies and implant-based breast reconstruction in patients with large and ptotic breast: oncological and reconstructive results. *Breast* 2012 Jun;21(3):267–71.
  - [31] Caputo GG, Marchetti A, Dalla Pozza E, et al. Skin-reduction breast reconstruction with prepectoral implant. *Plast Reconstr Surg* 2016 Jun;137(6):1702–5.