

Treatment of Hyperhidrosis With Microwave Technology

Carolyn Jacob, MD*,†

Hyperhidrosis is the production of sweat above and beyond normal physiological needs, regardless of the ambient temperature, and it affects >4% of the population. In addition, a poll showed up to 21% of the population is bothered on a daily basis by their amount of underarm sweating. Despite the large number of patients who suffer from hyperhidrosis, there are relatively few effective nonsurgical treatment options. A new, nonsurgical, lasting treatment for axillary hyperhidrosis has now been developed using microwave technology to eliminate sweat glands.

Semin Cutan Med Surg 32:2-8 © 2013 Frontline Medical Communications

KEYWORDS primary hyperhidrosis, microwave technology, electric dipoles, thermolysis, eccrine glands

Hyperhidrosis is characterized by the abnormal production of perspiration beyond that which is needed to regulate body temperature. It can affect the axilla, palms, soles, back, forehead, chest, and groin. Some patients suffer from multiple areas of hyperhidrosis. Sweat is produced through 2 types of sweat glands, eccrine and apocrine. There is also a combination of the 2 glands known as the apoeccrine gland. Eccrine glands produce the clear odorless fluid that we typically associate with sweat. They are the only true sweat gland in humans, and are abundant throughout all skin surfaces, except the vermilion border of the lips, labia minora, clitoris, glans penis, inner aspect of the prepuce, external auditory canal, and nail beds. The greatest number is located on the palms, soles, and axillae. They are located primarily at the dermal-subcutaneous junction and are composed of the secretory gland, a coiled duct, and the intradermal duct that travels through the dermis to connect to the spiraled intra-epidermal duct (acrosyringium) (Fig. 1).^{1,2} The major function of the eccrine glands is to produce the hypotonic solution known as sweat, which facilitates evaporative cooling.

Cholinergic nerves of the sympathetic nervous system innervate eccrine glands, producing acetylcholine, which acts on the plasma membrane of pale cells, beginning the metabolic process leading to sweat formation. Both thermal and emotional factors prominently stimulate sweating. Apocrine glands, in contrast, are found only in the axilla, anogenital region, external auditory canals, and eyelids, and uncommonly on the face and scalp.^{3,4} They produce a viscous substance that is released intermittently and is acted on by bacteria, which results in a characteristic odor. They are also located at the level of the lower dermis or subcutaneous fat.

Symptoms of Hyperhidrosis

Although heat is usually responsible for an increase in sweating of the hair-bearing surfaces of the body, emotional stimuli control sweating of the palms and soles, as well as, in some patients, the axillae. There is evidence that patients with palmar and plantar hyperhidrosis have overstimulation of the sympathetic nerves. During sleep, hyperhidrotic individuals sweat normally.⁵ In addition, patients with axillary hyperhidrosis usually do not have bromhidrosis (abnormal sweat odor).

There are different ways to measure hyperhidrosis. The hyperhidrosis disease severity scale (HDSS) was developed by the International Hyperhidrosis Society to quantify degrees to which underarm sweating alone bothers patients. Patients are rated on a 4-point scale regarding tolerability of sweating, and interference with daily activities (Table 1). A multispecialty working group on the recognition, diagnosis,

*Department of Dermatology, Northwestern Feinberg School of Medicine, Chicago, IL.

†Chicago Cosmetic Surgery and Dermatology, Chicago, IL.

Disclosures: The author has completed and submitted the ICMJE Form for Disclosure of Potential Conflicts of Interest. Dr Jacob is a Board Member of Miramar.

Correspondence: Carolyn Jacob, MD, Department of Dermatology, Northwestern Feinberg School of Medicine, Chicago Cosmetic Surgery and Dermatology, 20 W. Kinzie Street, Suite 1130, Chicago, IL 60654. E-mail: cjacob@chicagodermatology.com

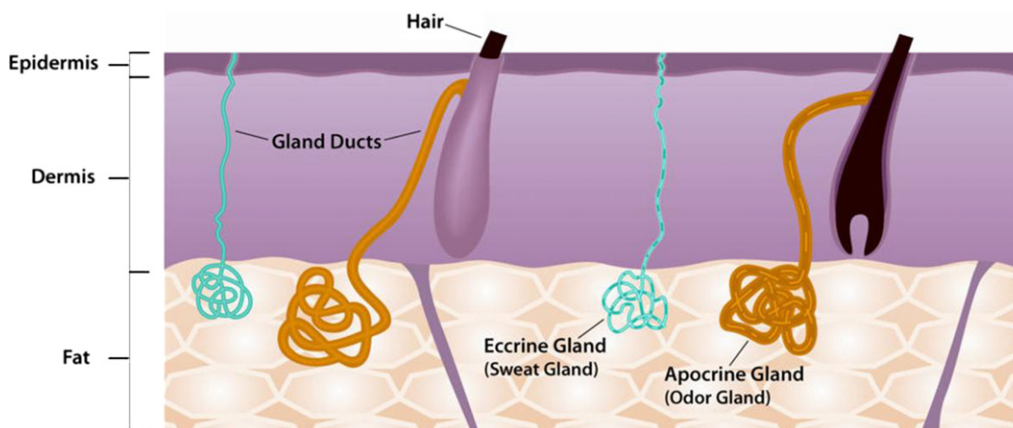


Figure 1 Eccrine and apocrine glands and their location in the skin. (Miramar Labs, Inc.)

and treatment of primary focal hyperhidrosis developed consensus criteria for the diagnosis consisting of hyperhidrosis for > 6 months, plus 2 of the following: bilateral and symmetric occurrence, impairment of daily activities, > 1 episode per week, age of onset < 25 years, family history, and cessation during sleep.⁶

Treatment Options

Topicals

There are several topical medications available to reduce sweating. A 12%-20% solution of aluminum chloride can be applied to the affected areas at night, beginning with once or twice a week and gradually increasing to nightly. The aluminum temporarily occludes the sweat ducts. This can be effective but can also cause irritant contact dermatitis, especially in the axillae, which often limits its use. Patients also complain that the solution works for awhile, and then seems to lose its efficacy. If 20% aluminum chloride is not effective, occlusion with plastic wrap at night for 2-3 nights a week can be performed. There is a less common topical consisting of 0.1% formalin in which a patient can soak several times a week. Alternatively, 2%-10% glutaraldehyde or 10% tannic acid in 70% alcohol can be painted on the involved areas daily.⁷ However, each of these solutions must be compounded, and it can be difficult to find compounding pharmacies that can create these solutions for patients.

Table 1 Hyperhidrosis disease severity scale

"How Would You Rate the Severity of Your Hyperhidrosis?"
1 My sweating is never noticeable and never interferes with my daily activities
2 My sweating is tolerable but sometimes interferes with my daily activities
3 My sweating is barely tolerable and frequently interferes with my daily activities
4 My sweating is intolerable and always interferes with my daily activities

A new topical formulation containing 15% aluminum chloride and 2% salicylic acid gel showed 75% of 30 patients were somewhat or very satisfied with treatment. Mean HDSS scores decreased from 3.3 at baseline to 2.12 by week 12.⁸ The medication was applied once nightly for 1 week and then twice daily for the remaining 11 weeks. The nonalcohol gel base is less irritating than alcohol bases.⁹ Topical anticholinergics, such as 2% glycopyrrolate, may also be of benefit.¹⁰ In addition, for palmar and plantar hyperhidrosis, one can use tap water iontophoresis, which theoretically works by plugging the pores of the sweat gland or by a complex mechanism involving changes in reabsorption of sodium.¹¹

Oral Anticholinergics

For those in whom topicals are ineffective, oral anticholinergics can be used alone or in combination with topicals. These oral anticholinergics include glycopyrrolate and propantheline bromide.¹² However, few controlled studies have been done. Side effects from oral glycopyrrolate and propantheline bromide include dry mouth, dry eyes, loss of urinary bladder sphincter control, and reduction of gastrointestinal peristalsis. Other oral medications that have been used include paroxetine and clonidine.¹³

Surgery

Surgical methods can be used to eradicate the sweat glands directly or to denervate the sympathetic flow to the upper torso and head. For resistant localized axillary hyperhidrosis, direct excision of the sweat glands under visualization has been performed. However, it is not uncommon for eccrine sweat glands outside the original hyperhidrotic area to overcompensate gradually after surgery with increased sweating.¹⁴ Liposuction with tumescent anesthesia using a blunt or specialized cannula to rasp the underside of the dermis has also been used.¹⁵⁻¹⁷ As with any liposuction procedure, patients will have some swelling and discomfort, and will require healing time. As a last resort, patients can undergo an endoscopic transthoracic sympathectomy, whereby the lumbar and supraclavicular sympathetic ganglia (the second to fourth thoracic ganglia) are ablated or clamped. The most

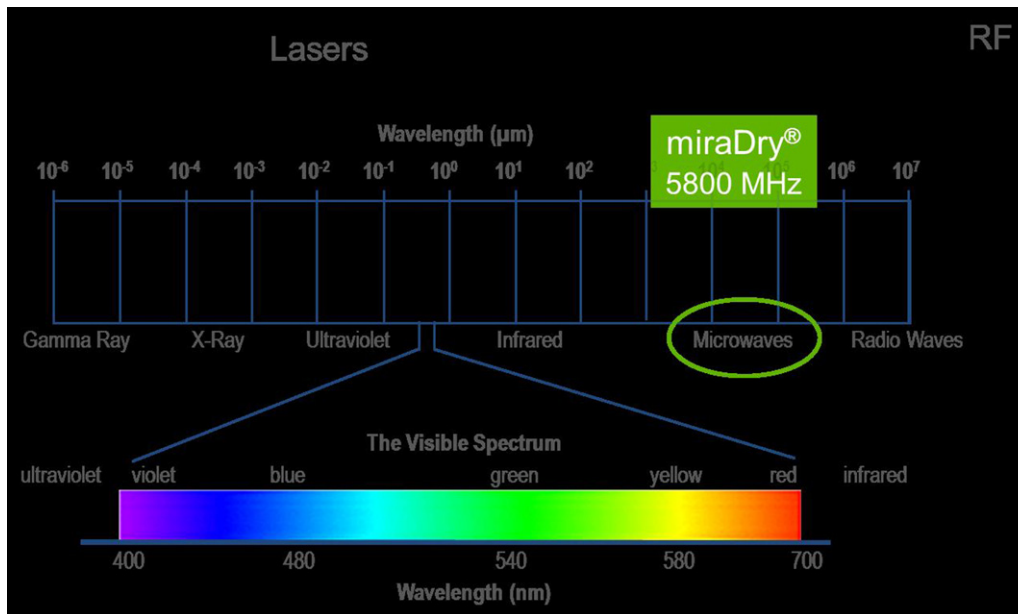


Figure 2 Electromagnetic spectrum with location of microwaves. (Miramar Labs, Inc.)

common side effect from endoscopic transthoracic sympathectomy surgery is compensatory hyperhidrosis of the lower portion of the body (below T4).¹⁸

Devices

Lasers and other devices have also been recently used to attempt to treat primary axillary hyperhidrosis. A long-pulsed neodymium yttrium aluminum garnet (Nd:YAG) laser at hair reduction settings showed improvements in subjective and objective measures of sweating up to 9 months, but with no differences in histology of the axillary skin.¹⁹ A long-pulsed 800-nm diode laser was used to treat 21 patients on 1 axilla only but failed to show a significant sweat reduction compared with the untreated side.²⁰ Invasive use with the 1320-nm laser for subdermal ablation has shown to give satisfactory improvement in 1 patient.²¹

Injections

Injections of botulinum toxin type A have been shown to decrease axillary hyperhidrosis for 6-9 months, but treatment for palmar and plantar hyperhidrosis is less effective, and treatments need to be performed indefinitely to maintain results.²²

Microwave Technology for Treatment of Hyperhidrosis

Given the paucity of treatments for primary axillary hyperhidrosis that are effective, lasting, and have no side effects, a new treatment involving microwave energy was developed for the nonsurgical reduction of sweating. Microwaves lie in the electromagnetic spectrum between infrared waves (such as carbon dioxide lasers) and radiowaves (radiofrequency devices) at 10^4 - 10^5 μm (Fig. 2). Microwaves travel at the

speed of light and are used to transmit information or power. They are commonly used for cell phones, wireless routers, radar, and heating, such as in a microwave oven. Microwaves heat substances through a process called dielectric heating. Electric dipole molecules rotate in response to microwaves in an attempt to align with the alternating electromagnetic field. Rapid movement causes frictional heat. Water has a high dipole moment, which means it is highly absorbent for microwaves, whereas fat has a low dipole moment and absorbs microwaves poorly (Fig. 3). As the microwaves are preferentially absorbed by high-water-content tissue, this leads to localized heating. Microwaves were first introduced for medical use in the 1970s in the form of surgical coagulation devices.

The microwaves can penetrate to depths where eccrine glands are found. This depth is achieved by the use of an

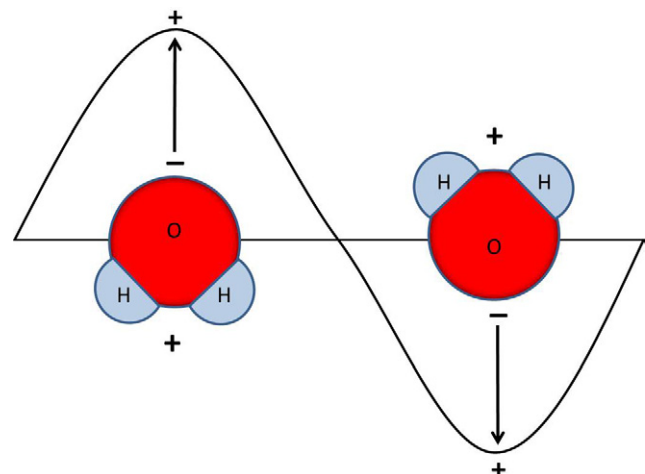


Figure 3 Electric dipole rotation. (Miramar Labs, Inc.)

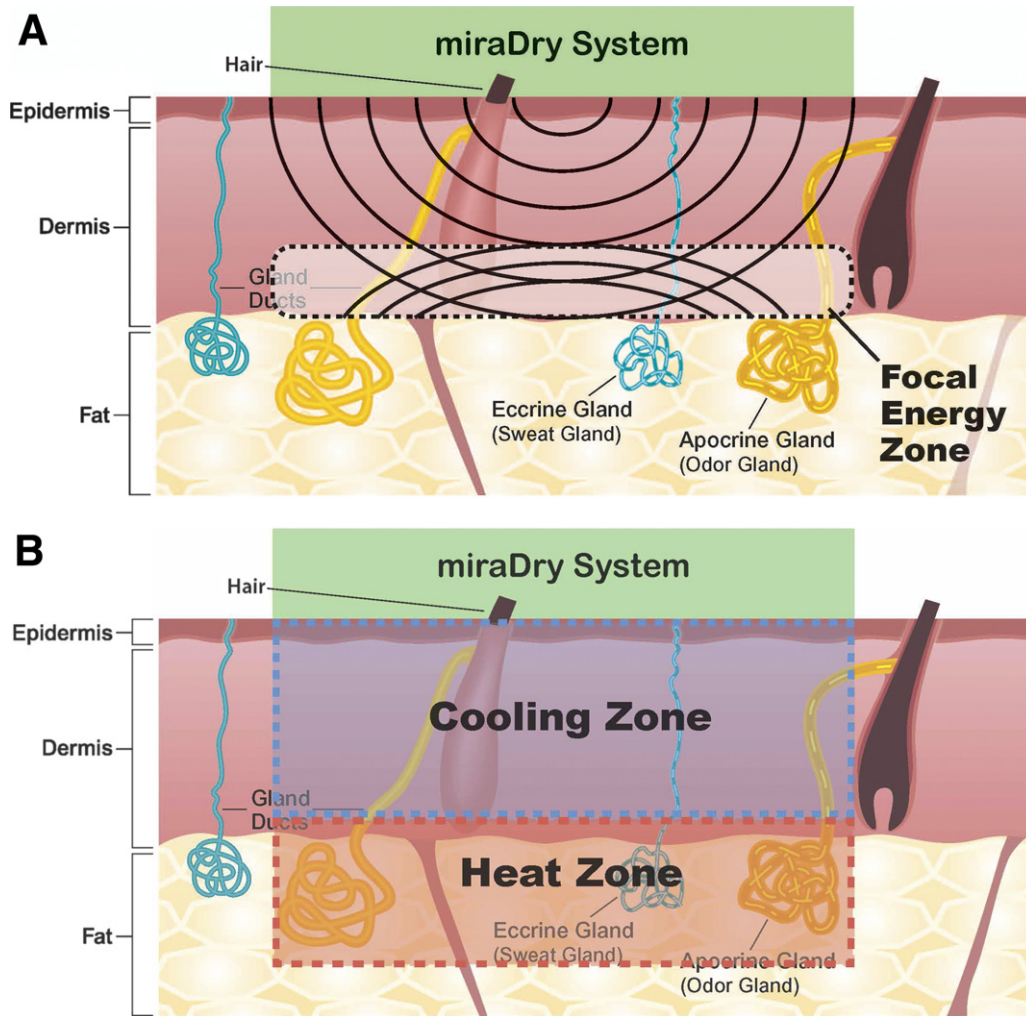


Figure 4 Microwave energy concentrated along dermal–fat interface with cooling to prevent thermal conduction of heat superficially. (Miramar Labs, Inc.)

antenna that preferentially targets the skin–adipose interface, where most eccrine glands reside. There is an extremely dense network of sweat glands in the axillae (>50,000), and their depth can vary from 2 to 5 mm below the skin surface, depending on the patient’s skin thickness. The microwave energy is concentrated along the dermal–adipose, creating a focal energy zone. At the same time, continuous hydroceramic cooling prevents thermal conduction of heat superficially. The heat at the dermal–adipose energy zone leads to thermolysis of the eccrine glands (Fig. 4).

The miraDry (Miramar Labs, Sunnyvale, CA) device consists of a console, handpiece, and a single-use disposable bioTip (Fig. 5). The console contains the proprietary computer software, a chiller and pump, and a vacuum pump. The handpiece contains 4 antennae, covers a 10 × 30-mm zone of therapy per treatment cycle (several cycles are involved in 1 full axillary treatment), and allows the active cooling to protect the epidermis and dermis. The bioTip uses the vacuum pump to lift the skin away from underlying structures, such as nerves, and stabilizes the skin during the therapy cycle. It is sterilized to protect the patient and prevent contamination of the equipment. There are 5 energy settings that

determine the volume and depth of treatment. The power is constant across all energy settings. A higher energy setting allows the heat to be delivered over a longer period. Therefore, time is used to adjust the energy levels delivered. The miraDry device has a frequency of approximately 5800 MHz (5.8 GHz). Two hours before treatment, patients are instructed to take 800 mg of ibuprofen with food. This is to help with posttreatment edema and tenderness. Treatments require first shaving 4 days before the procedure and cleaning the axillae on the day of treatment with alcohol, and then measuring the size of the vault. The axillary vault size is determined by the amount and distribution of the sweat as seen visually or through a starch–iodine test. During a starch–iodine test, iodine is painted on the clean axillae, and starch is brushed over the area lightly. After several minutes, the sweat that is produced will mix with the starch and iodine, turning the hyperhidrotic surface area black in color (Fig. 6). The starch–iodine mixture is removed before treatment.

After wiping the area with alcohol, the axillary vault is measured. Grids of varying size from 60 to 120 mm are supplied, and the largest length of vault size is marked with a

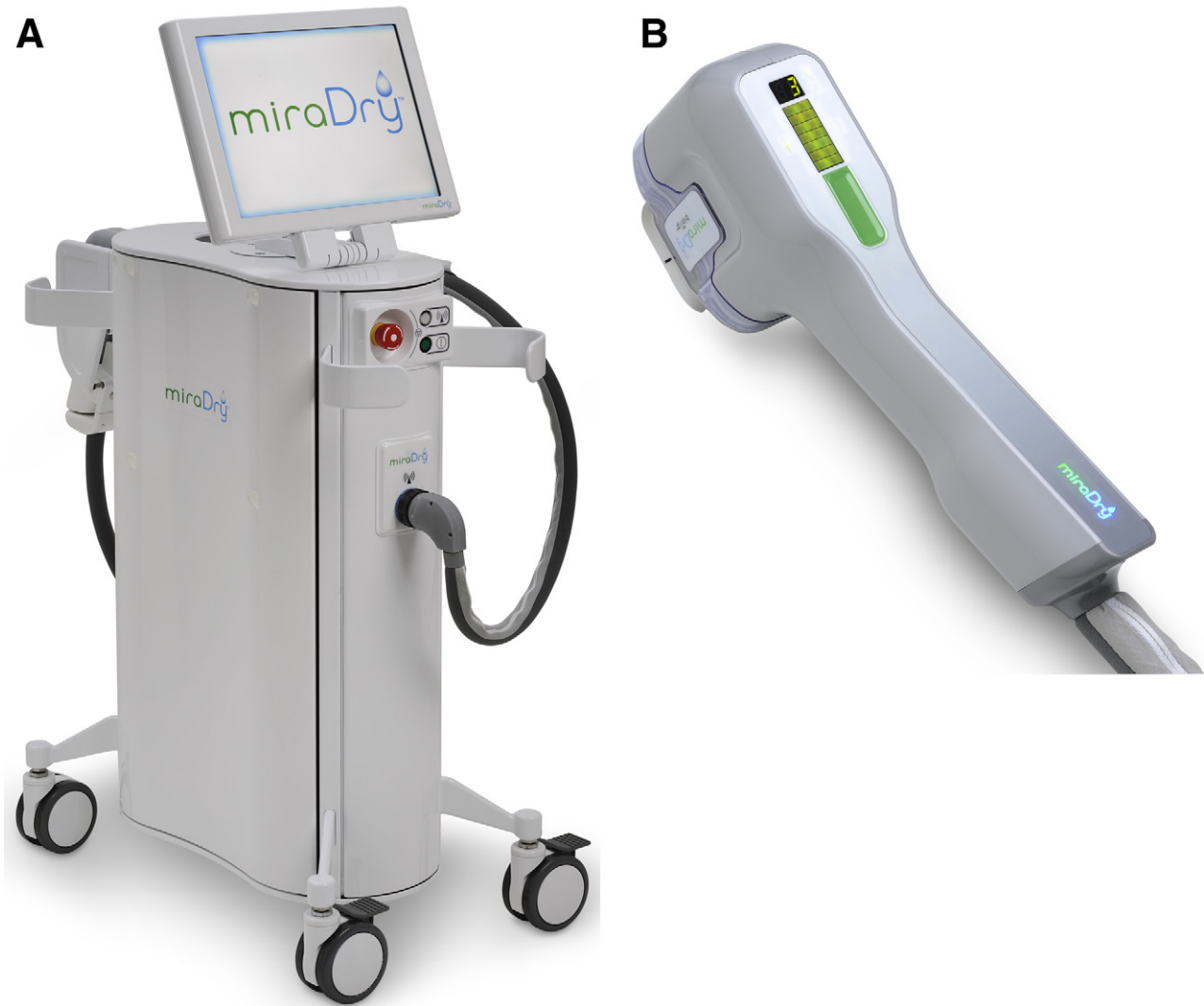


Figure 5 The miraDry console, handpiece, and bioTip. (Miramar Labs, Inc.)

pen. An oval template, conforming to the measured size, is then applied to the vault using alcohol swabs. This template delineates the treatment zones (10 × 30 mm) with handpiece alignment lines and tick marks to guide treatment of the entire vault, and the sites for injection of anesthesia (Fig. 7).

After application of the grid, anesthetic consisting of 50% of 1% lidocaine plain and 50% of 1% lidocaine plus epineph-

rine is used to anesthetize the dermis, with injections spaced approximately every 1 cm. The lidocaine with epinephrine is used to increase the amount of lidocaine that can safely be used, as the upper limits for toxicity are 4 mg/kg for plain lidocaine and 7 mg/kg for lidocaine with epinephrine. Depending on the size of the axillary vault, some patients need up to 25 mL per axilla. For time savings, a separate assistant

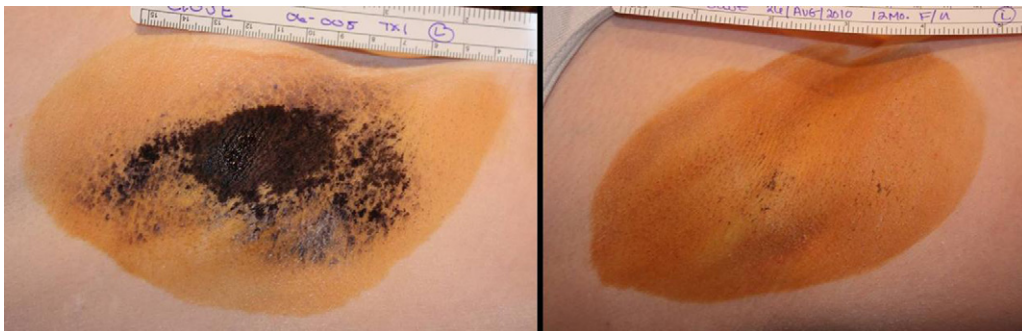


Figure 6 Starch-iodine test showing darkening where sweat is abundant before treatment and lack of darkening after treatment. (Miramar Labs, Inc.)

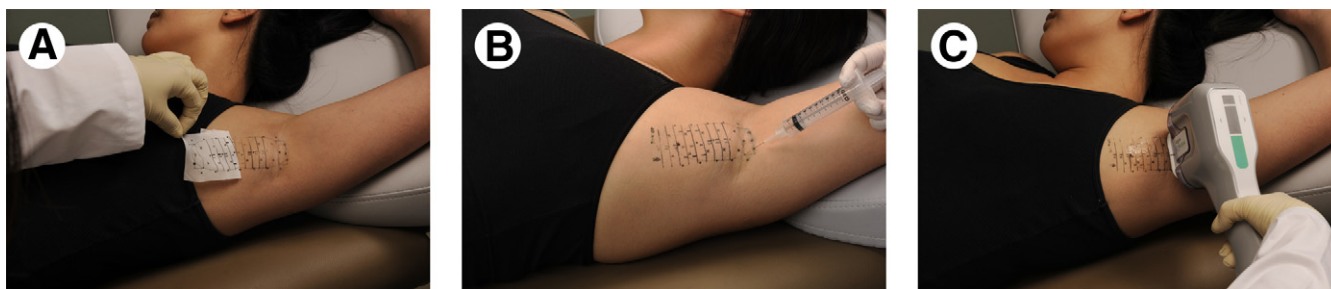

Figure 7 Placement of the temporary treatment grid, administration of local anesthesia, and positioning of the hand piece for the MiraDry treatment. (Miramar Labs, Inc.)

can anesthetize the second axillary vault while the practitioner begins the treatment on the first anesthetized axilla.

Each application of the bioTip over the treatment zone allows for the vacuum action to pull the skin away from the underlying structures, followed by application of the appropriate energy. It is recommended that the first 3 treatment zones most superior (closest to the distal portion of the raised upper arm) should be treated at a level of 1 (lower energy) to prevent overheating of the thinner-skinned areas and underlying nerve structures. The remaining treatment zones (closer to the trunk) can be treated at a level of 1-3 for the first full treatment. In subsequent treatments, higher levels can be used if the skin is thicker and the patient experiences a normal posttreatment course. Each treatment zone takes approximately 45 seconds to treat (less time for level 1, more time for level 5), leading to a total treatment time of approximately 25 minutes per axilla after anesthesia.

After treatment, patients are given 2 ice packs wrapped in gauze to place under the axillae for 20 minutes, and they are instructed to take 400 mg of ibuprofen with food every 4-6 hours while awake for 3 days, unless contraindicated. The patient should reuse the ice packs every 3-5 hours, as needed for comfort. Instruct the patient to place gauze between the ice pack and the skin so that it is not in direct contact with the skin. If the ice pack is in direct contact with the skin, it could lead to skin damage. Most patients experience mild edema and discomfort for 3 days, with a sensation described as "having a softball under their arm." This is normal. Rarely,

patients will develop edema outside of the treatment area, often in the dependent portion of the underarm and upper chest. This will resolve over several days with the aforementioned posttreatment care. It is also recommended to rest the arms for 3 days (limiting activities). Other common side effects include redness from the device suction, bruising at the injection sites, temporary bumps or lumpiness in the axilla, partial underarm hair loss, and altered sensation in or around the treatment area.

Patients are scheduled for a second treatment 3 months after the initial treatment. A study by Drs. Chi-Ho Hong and Lupin on 31 patients showed 90% efficacy persisting after 12 months. Efficacy was defined as a drop in HDSS from 3 or 4 to a 1 or 2. Patient satisfaction was also rated as 90% at 12 months after the treatments. The average patient's sweat was reduced by 82%.²³ Histology data show sweat gland necrosis at 11 days post treatment and reduction of sweat glands 6 months after treatment (Fig. 8). Further follow-up on these patients showed > 100% efficacy and > 100% patient satisfaction results at 18 months (Fig. 9).²⁴

Conclusions

The treatment of primary axillary hyperhidrosis can be rewarding using noninvasive microwave technology. Because the microwaves preferentially target the region of skin where the sweat glands reside, leading to localized thermolysis of the sweat glands, patients can now benefit from permanent

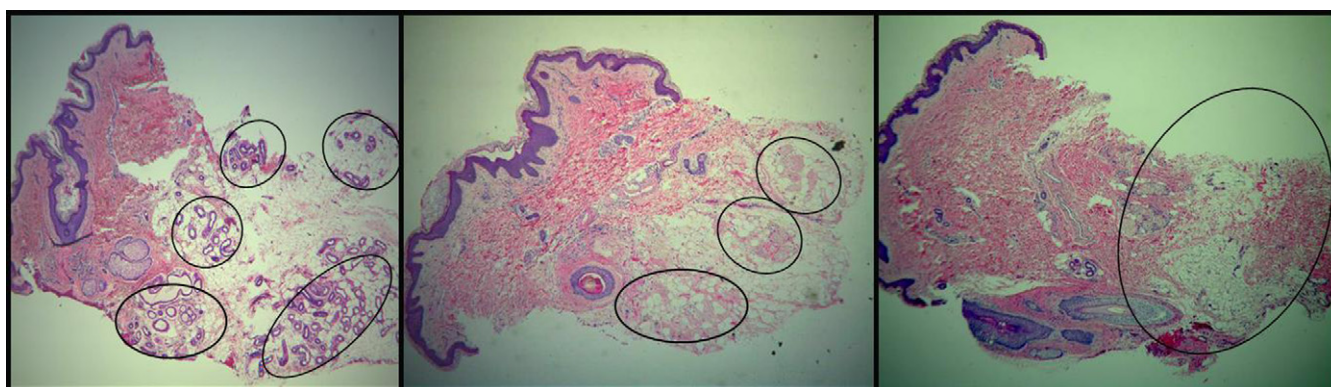


Figure 8 Histologic data showing normal sweat glands, sweat gland cells with necrosis, and absence of sweat glands at 6 months. (Samples provided courtesy of Dr. Kushikata.)

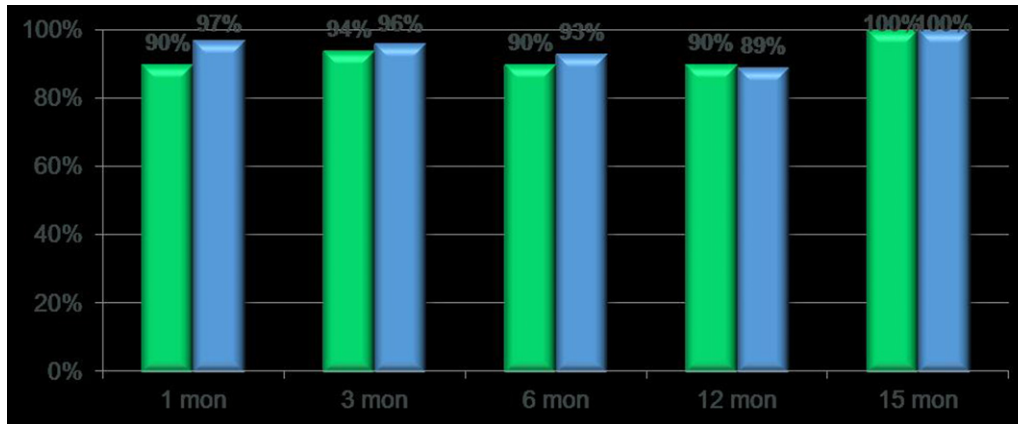


Figure 9 Long-term efficacy (green bar) and patient satisfaction after 2 microwave treatments for axillary hyperhidrosis.

targeted sweat reduction. The microwave treatment has been shown to be safe and effective in >6000 procedures to date. Further clinical trial and practice experience will lead to tighter parameters, which will likely decrease minor side effects and increase patient satisfaction.

References

1. Hashimoto K. The eccrine gland. In: Jarrett A, ed. *The Physiology and Pathophysiology of the Skin*. Vol 5. New York: Academic Press; 1978; 1543-1573.
2. Sato K. The physiology and pharmacology of the eccrine sweat gland. In: Goldsmith ZA, ed. *Biochemistry and Physiology of the Skin*. Oxford, England: Oxford University Press; 1983;596-641.
3. Ito M, Suzuki M, Motoyoshi K, et al. New findings on the proteins of sebaceous glands. *J Invest Dermatol*. 1984;82:381-385.
4. Craigmyle MBL. *The Apocrine Glands and the Breast*. Chichester, England: John Wiley & Sons; 1984.
5. Hurley HJ. The eccrine sweat glands. In: Moschella SL, Pillsbury DM, Hurley HJ, eds. *Dermatology*. Philadelphia: W. B. Saunders; 1975; 1167-1175.
6. Hornberger J, Grimes K, Naumann M, et al. Recognition, diagnosis, and treatment of primary focal hyperhidrosis. *J Am Acad Dermatol*. 2004; 51:274-286.
7. Coleman WP III, Sato K, Kane N, et al. Biology and disorders of sweat glands. In: Arndt K, et al, eds. *Cutaneous Medicine and Surgery*. Philadelphia, PA: W. B. Saunders; 1996;1311-1319.
8. Flanagan KH, Glaser DA. An open-label trial of the efficacy of 15% aluminum chloride in 2% salicylic acid gel base in the treatment of moderate-to-severe primary axillary hyperhidrosis. *J Drugs Dermatol*. 2009;8:477-480.
9. Newman JL, Seitz JC. Intermittent use of an antimicrobial hand gel for reducing soap-induced irritation of health care personnel. *Am J Infect Control*. 1990;3:194-200.
10. Kim WO, Kil HK, Yoon KB, et al. Topical glycopyrrolate for patients with facial hyperhidrosis. *Br J Dermatol*. 2008;158:1094-1097.
11. Ohshima Y, Shimizu H, Yanagishita T, et al. Changes in Na⁺, K⁺ concentrations in perspiration and perspiration volume with alternating current iontophoresis in palmo-plantar hyperhidrosis patients. *Arch Dermatol Res*. 2008;300:595-600.
12. Lee HH, Kim do W, Kim do W, et al. Efficacy of glycopyrrolate in primary hyperhidrosis patients. *Korean J Pain*. 2012;25:28-32.
13. Praharaj SK, Arora M. Paroxetine useful for palmar-plantar hyperhidrosis. *Ann Pharmacother*. 2006;40:1884-1886.
14. Bretteville-Jensen G, Mossing N, Albrechtsen R. Surgical treatment of axillary hyperhidrosis in 123 patients. *Acta Derm Venereol*. 1975;55:73-77.
15. Shenaq SM, Spira M, Christ J. Treatment of bilateral axillary hyperhidrosis by suction assisted lipolysis technique. *Ann Plast Surg*. 1987;19: 548-551.
16. Coleman WP III. Noncosmetic applications of liposuction. *J Dermatol Surg Oncol*. 1988;14:1085-1090.
17. Lillis PJ, Coleman WP III. Liposuction for treatment of axillary hyperhidrosis. *Dermatol Clin*. 1990;8:479-482.
18. Bogokowsky H, Slutzki S, Bacalu L, et al. Surgical treatment of primary hyperhidrosis. A report of 42 cases. *Arch Surg*. 1983;118:1065-1067.
19. Letada PR, Landers JT, Uebelhoefer NS, et al. Treatment of focal axillary hyperhidrosis using a long pulsed Nd: YAG 1064nm laser at hair reduction settings. *J Drugs Dermatol*. 2012;11:59-63.
20. Bechara FG, Georgas D, Sand M, et al. Effects of a Long-pulsed 800-nm Diode laser on axillary hyperhidrosis: A randomized controlled half-side comparison study. *Dermatol Surg*. 2012;38:736-740.
21. Kotlus BS. Treatment of refractory axillary hyperhidrosis with a 1320-nm Nd: YAG laser. *J Cosmet Laser Ther*. 2011;13:193-195.
22. Doft MA, Hardy KL, Ascherman JA. Treatment of hyperhidrosis with botulinum toxin. *Aesthet Surg J*. 2012;32:238-244.
23. Hong HC, Lupin M, O'Shaughnessy KF. Clinical evaluation of a microwave device for treating axillary hyperhidrosis. *Dermatol Surg*. 2012; 38:728-735.
24. Lupin M, Hong HC-H, O'Shaughnessy KF. Long-term evaluation of microwave treatment for axillary hyperhidrosis. *Lasers Surg Med*. 2012; 44:6.